

EXAM COMMITTEE
12TH BATCH

NEU 241 MIDTERM

Collected By: 12th Batch

MCQS QUESTIONS

1. Which one cause secondary hyperalgesia?

A. Substance P
B. Bradykinin
C. Histamine
D. ATP

Ans: A

2. A test on a patient was done by a toning fork to test his ability to sense vibration. which receptor is for high frequency vibrations and pressure?

A. Meiissniers courpuscle
B. pacinian corpuscle
C. Ruffini

Ana: B

3. In the norepinephrine pathway, which of the following is activated?

A. Adenyl cyclase
B. Phospholipase C
C. IP3

Ans: A

4. Golgi tendon reflex by which fibers?

A. 1b afferents
B. 1a afferents

Ans: A

5. A junior resident in medicine rapidly treated hyponatremia in a patient. A few days later, the patient developed quadriplegia. The brain MRI would show demyelination of which part of the brain?

A. Crus cerebri of midbrain
B. Posterior limb of internal capsule
C. Basilar part of pons
D. Pyramids of medulla
E. Tegmentum of pons

Ans: C

6. A 30- year-old patient present with acute abdomen, acute appendicitis was suspected, and he was administered an intravenous analgesic. 15 minutes later, his BP and HR increased, and he complained of a state uneasiness. Which of the following receptors were activated by the analgesic?

A. Delta
B. Alpha
C. Kappa
D. Beta
E. Mu

Ans: C

7. A 40-year-old male who been suffering from a disorder of unknown origin complains to his physician that he has difficulty in producing a smile from the left side of his face, and he can't salivate or produce tears from the left eye. Further analysis showed some loss of taste and that affected muscles were flaccid, and the eyelids were open. The paraganglionic parasympathetic fibers of the nerve involved in this case arise from which of the following?

A. Inferior salivatory nucleus
B. Superior salivatory nucleus
C. Edinger-Westphal nucleus of cranial nerve III
D. Dorsal motor nucleus of the vagus
E. Nucleus ambiguous

Ans: B

8. 22-year-old Zafar had multiple stab wounds in the back while resisting an attempt robbery, an MRI done the next day shown a hemi-section of the spinal cord at the level of the left T6 vertebrae. Which of the following spinal segments corresponds to the T6 vertebrae?

   A. L1
   B. T10
   C. T8
   D. T11
   E. T9

Ans: C

9. A 56-year-old man with higher than normal language output and frequent paraphasic errors. Testing reveals that his comprehension of auditory and visual language is severely disturbed. He also exhibits inability to repeat language. This patient had which of the following aphasia?

   A. global
   B. transcortical
   C. conduction
   D. Wernicke's
   E. Broca's

Ans: D

10. A 50-year-old hypertensive woman complains of numbness and weakness in her leg and foot. Occlusion of which of the following vessels may account for this complaint?

   A. anterior cerebral artery
   B. posterior cerebral artery
   C. internal carotid artery
   D. anterior choroidal artery
   E. middle cerebral artery

Ans: A

11. Descending neurons from which of the following structures is involved in the modulation of pain via the release of serotonin?

    A. Locus coeruleus
    B. Periaqueductal gray area
    C. Periventricular area
    D. Interneurons of the spinal cord
    E. Nucleus raphe magnus

Ans: E

12. A 15 year old girl is brought to the clinic by her mother because she is experiencing right sided weakness in her face. Her mouth was pulled to the left. There was weakness of her right facial muscles. There was normal skin sensation on her face. Her right eye was deviated medially and she was unable to abduct it. She had spastic paralysis of her left arm and leg. At which site was the lesion?

    A. Right medulla
    B. Midbrain
    C. Left medulla
    D. Left pons
    E. Right pons

Ans: E

13. Where is serotonin secretion from?

    A. Raphe nuclues
    B. Locus

Ans: A

14. A question about how botulism affect neurons?

    A. Targets excitatory motor neurons
    B. Targets inhibitory interneurons

Ans: A

15. What enzyme is responsible for breakdown of catecholamines?

    A. Monoamine Oxidase

16. Patient developed right sided ptosis and lateral strabismus after a stroke. He also had left sided spastic paralysis. MRI would show a stroke involving which part of the brain?

    A. Crus Cerebri

17. A question about distal hand weakness and spasticity?

    A. Cortex

18. A question about a drug that increase BP and HR and causes uneasiness to the patient?

    A. Pentazocine

19. A question about a heroin addict who was in prison. What drug should we use?

    A. Methadone

20. Damage to the blood CSF barrier. What will happen after that?

    A. Increase sodium
    B. Increase albumin

Ans: B

21. Which area is exposed to toxins in the brain?

    A. Area postrema

22. A patient is brought to a neurological clinic by his wife because he was only shaving the left side of his face and shampooing the left side of his head. Where could the lesion be? (a similar question but he changed the side)

A. Left parietal lobe
B. Right parietal lobe
C. Left occipital lobe
D. Right temporal lobe
E. Left frontal lobe

ANS : A

23. A person has a block of the right anterior cerebral artery. What would he suffer from ?

A. Loss of pain and temp on the left lower limb
B. Weakness in the left lower limb
C. Spastic Paralysis of lower limb
D. Pulmonary edema

Ans: A

24. A question about where IDH 1 and IDH 2 are common?

A. Low grade astrocytomas
B. Gliobastoma

Ans: A

25. Which drug is contraindicated for migraine if patient is asthmatic?

A. Propranolol

26. Which of the following induces the least migraine?

A. Chocolate
B. Keto diet
C. Exercise

Ans: B

27. Which patient doesn't need further investigation to diagnose?

A. A patient with chronic migraine

28. which of the following regions of the body has the largest representation in the primary motor cortex (Brodmann area 4)?
A. forearm
B. thumb
C. trunk
D. mastication muscles

Ans: B

29. A question about antoni A areas and antoni B areas. What is this type of tumor?

A. Shawanoma
B. Gliobastoma
C. Ependymoma

Ans: A

30. An impairment in the ability to perform certain types of learned, complex movements (referred to as apraxia) usually results from a lesion of which of the following?

A. Precentral gyrus
B. Postcentral gyrus
C. Premotor cortex
D. Prefrontal cortex
E. Primary motor cortex

Ans: C

31. A Physiology question about cl equilibrium potential and resting potential

A. hyperpolarization when cl moves in

32. They got this picture with a clinicals cenario and asked about the type of tumor?

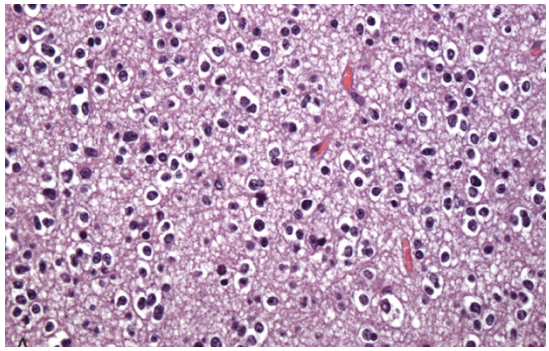

A. Glioblastoma
B. Oligodendroglioma

Ans: B

33. What is the key determinant of the resting membrane potential?

A. Potassium
B. Sodium
C. Chloride

Ans: A

34. They got a picture similar to this and asked about the receptor response?

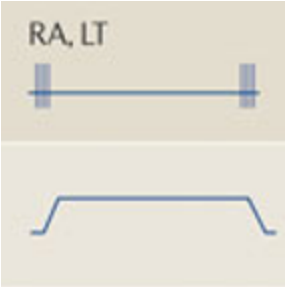

A. Rapid adapting
B. Slow adapting

Ans: A

35. A question about a person with depression on fluxotine, which drug is contraindicated for acute treatment of migraine?
A. sumitriptan
B. propranolol

36. local anaesthetic for a long surgery procedure

A. Bupivacaine

37. There was a question about why we use epinephrine with local anesthetics?

A. To increase absorbtion
B. To increase duration

Ans: B

38. A question about enkephalins and their action?

A. Close VGCC on presynaptic nerve terminals
B. Hyperpolarize and inhibit post-synaptic by opening potassium channels

Ans: B

39. A question about pentozocine and the answer was withdrawal symptoms

40. There were 2 pathology questions about symmetrical degeneration of neurons and the answer was axonal degeneration/neuropathy

41. A question about chromatolysis and how does it appear?

A. Enlarged pink cytoplasm
B. dispersion of nissl bodies

Ans: B

42. Synaptotagmin and in which process its involved in synaptic transmission?

A. Fusion
B. Docking
C. Priming

Ans: A

43. A Physiology question about muscle weakness and myositis and no antibodies against acetylcholine receptor and tyrosine kinase and the answer was SNARE proteins.

44. Crux cerebri damage and loss of accommodation. What is the sight of damage ?

A. Tegmentum of pons
B. Tectum of pons

45. Defect in right sided facial nucleus?

A. Upper pons
B. Lower pons
C. Crus cerebri

46. A question about a patient with history of respiratory infection?

A. Inflammation